

# Surgical Management of Supracondylar Fractures of the Humerus in Children by Closed Reduction and Percutaneous Pinning with Kirschner Wires: A Cross-sectional Study

CHAVAN PRAMOD BABU<sup>1</sup>, K SHANKARA<sup>2</sup>, T LAKSHMEESHA<sup>3</sup>

## ABSTRACT

**Introduction:** Supracondylar Humerus Fracture (SCHF) is frequently encountered in paediatric age group and constitutes nearly three fourth of all upper extremity fractures. Most commonly used technique for surgical treatment in the displaced SCHF in children is closed reduction and stabilisation with percutaneous pins.

**Aim:** To find out the outcome and safety of percutaneous pinning techniques in terms of functional and radiological outcome and to note the associated complications with this method of fixation.

**Materials and Methods:** This was a cross-sectional study, conducted on patients admitted to Department of Orthopaedics, Hassan Institute of Medical Sciences, Hassan, between January 2017 to December 2019. Thirty paediatric cases were retrospectively reviewed. These were admitted with a supracondylar fracture and had reported to the hospital over a three-year period. All fractures were treated with closed reduction and fixation with percutaneous Kirschner Wires (K-wire) followed by immobilisation in above elbow slab for three weeks. K-wires were removed at three weeks and mobilisation with physiotherapy was advised. Outcome was measured by Flynn's Criteria. The results were analysed as per appropriate descriptive statistical tests.

**Results:** The mean age of the patients was 7.4 years (range 4-12 years). Males outnumbered females. Total 22 (73.3%) patients had left-sided fracture and 8 (26.7%) had fracture on right side. Fracture union was seen in all the patients at a mean interval of 4.2 weeks (range 3-5 weeks), in a follow-up of 12 weeks. Most (90%) of the injuries were the result of trauma, including fall. 70% of the fractures were Gartland Type III supracondylar fracture. Cross K-wire fixation was done in 21 patients and lateral-only pin in 9 patients. Among the 21 patients, who had type III fracture, 4 of them were fixed with 2 Lateral K-wire pinning and 17 of them with crossed K-wire pinning configuration. The most common postoperative complication observed was a superficial pin tract infection, seen in 4 (13.3%) patients. Outcome according to the Flynn's criteria 25 patients (83.3%) had excellent result, 3 (10%) patients had good result, 1 (3.3%) had fair result and 1 (3.3%) patient had poor functional result.

**Conclusion:** The present study concludes that close reduction and percutaneous k-wire pinning techniques give a favorable outcome in displaced supracondylar fractures of the humerus in children, without any serious complications.

**Keywords:** K-wire configuration, Paediatric, Pin tract infection

## INTRODUCTION

Supracondylar Humerus Fracture (SCHF) is common in paediatric age group and constitute majority of the elbow fractures [1,2]. According to the direction of distal fragment, SCHFs in children is divided into extension type and flexion type. Gartland's classification is used to describe this fracture based on displacement in coronal plane radiographs and are of three types [2]. Type I are treated conservatively with an above-elbow plaster cast for three weeks with radiographs to look for displacements [3]. Type II and Type III usually go for malunion if treated with cast hence, they are treated with closed reduction and pinning [3]. Completely displaced supracondylar humeral fractures in children can present with brachial artery injury [4,5] and nerve injury in 20% of cases.

Percutaneous K-wire pinning techniques have become the preferred treatment in most of the supracondylar fractures because of difficulty in closed reduction and maintaining the reduction [6]. The commonly used pinning configurations are crossed pinning and only lateral pinning. A crossed pin configuration provides increased stability which is not the case with lateral pin fixation, while the disadvantage is ulnar nerve injury with the former that can be avoided with the latter [7-10].

Lateral only fixation is good enough for maintaining reduction while simultaneously avoiding injury to the ulnar nerve [11] but biomechanically less stable if not used in the proper configuration. The choice of pinning configuration is a surgeon's preference, as both configuration have their advantages and disadvantages.

This retrospective study was performed to find the advantages and safety of percutaneous pinning techniques with respect to functional and radiological outcome in the management of displaced supracondylar humerus fractures in children; and to note the associated complications with this method of fixation.

## MATERIALS AND METHODS

This was a retrospective study, performed on patients admitted to Department of Orthopaedics, Hassan Institute of Medical Sciences, Hassan, between January 2017 to December 2019. This study was approved by Institutional Ethical Committee {IEC-RR107/2019 (18-10-19)}.

**Inclusion criteria:**

1. Age 3-15 years
2. Gartland Type II and Type III fractures

3. Closed fractures
4. Fresh cases of fracture (within one week)

**Exclusion criteria:**

1. Associated other injuries at elbow
2. Malunited fractures
3. Floating elbow
4. Patients with inadequate follow-up and incomplete records

The patients with acute presentation to emergency department or outpatient department were admitted. As per protocol, primary splintage is done after assessing distal neuro-vascular status and patient sent for radiography. The study involved collecting data regarding the age of the patient, time to surgery from injury and duration of surgery using past records. Radiographs (anterior-posterior and lateral views) were reviewed to determine the type of Gartland fracture.

Radiographs were also used to determine the type of wire configuration used. All patients who were available for follow-up till 12 weeks with records were reviewed and 30 patients were included in the study. Postoperative complications along with their management were also noted. Union of fracture was assessed by absence of pain on movements and abnormal mobility clinically and radiological by adequate callus formation. The functional outcomes were assessed as per Flynn criteria [Table/Fig-1] [7].

Result	Carrying angle loss (Degrees)	Functional factor motion loss (Degrees)
Excellent	0-5	0-5
Good	6-10	6-10
Fair	11-15	11-15
Poor	>15	>15

[Table/Fig-1]: Flynn's Grading system.

**STATISTICAL ANALYSIS**

Statistical analysis was done using IBM Statistical Package for the Social Science (SPSS) software package for windows.

**RESULTS**

The study included 30 patients, of which 21 were males and 9 were females. The age of patients were in the range 4-12 years with a mean age of 7.4 years; 22 (73.3%) patients had left sided fracture and 8 (26.7%) patients had fracture on right side [Table/Fig-2].

Age (Years)	No. of patients	Percentage
4-6	12	40
7-9	8	26.7
10-12	10	33.3

[Table/Fig-2]: Age distribution of the study subjects.

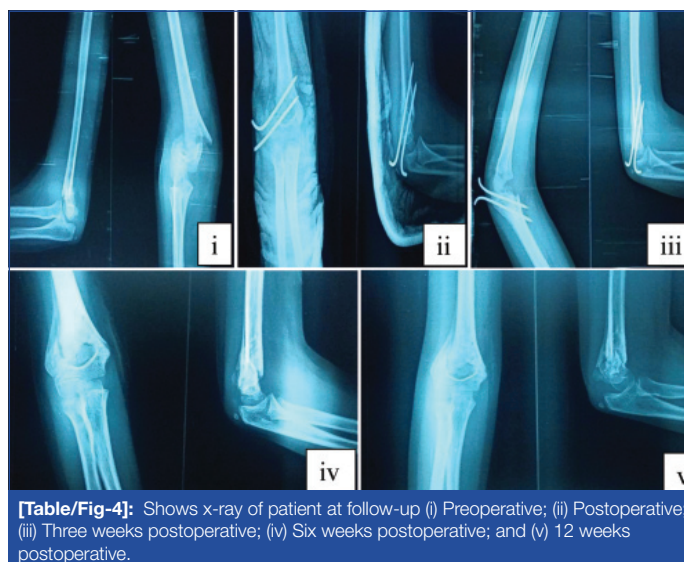
Most (90%) of the injuries were the result of trauma including fall. Out of the 30 cases, nine patients had Type II fracture and 21 of them had Type III fracture [Table/Fig-3]. Out of 30 patients, three had nerve injury due to fracture. Median nerve injury in 2 patients, radial nerve injury in 1 patient. All these nerve injuries did not require any separate surgical procedure as they recovered completely after fracture fixation within 6-12 weeks (mean 10 weeks). This was clinically assessed on follow-up by return of motor and sensory deficits but at the end of 12 weeks all had satisfactory results.

There was one patient with absent radial pulse and grossly displaced supracondylar fracture but well perfused. This patient was managed on an urgent basis with closed reduction and fixation of the fracture. The radial pulse was palpable after reduction. Out of 30 patients, associated fracture of ipsilateral distal radius and ulna was seen in 3 patients.

In this study, patients with both pin configuration were included cross K-wire was in 21 patients and lateral-only pin in nine patients. Of the 21 patients, who had type III fracture, 4 were treated with lateral only K-wire pinning and 17 were treated with crossed K-wire pinning configuration [Table/Fig-3,4].

Type of fracture	No. of patients	Cross pinning	Lateral-only pinning	Mean time for maximum ROM	Mean time for Union±SD
Type II	9 (30%)	4 (13.3%)	5 (16.6%)	8 weeks	4.1 weeks
Type III	21 (70%)	17 (56.6%)	4 (13.3%)	12 weeks	4.5 weeks
Total	30	21 (70%)	9 (30%)		4.2±0.7 weeks

[Table/Fig-3]: Gartlands classification. ROM: Range of motion



[Table/Fig-4]: Shows x-ray of patient at follow-up (i) Preoperative; (ii) Postoperative; (iii) Three weeks postoperative; (iv) Six weeks postoperative; and (v) 12 weeks postoperative.

Superficial pin tract infection was most common postoperative complication, observed in 4 (13.3%) patients after a mean time 12 weeks of follow-up. This was treated with removal of pin, oral antibiotics and daily cleaning and dressing, without any need for hospitalisation. All wounds healed well after removal of pins. Ulnar nerve injury was observed in 1 patient immediately after surgery due to medial K-wire. This recovered after removal of medial pin in 6 weeks. Stiffness of elbow was seen in 3 (10%) patients. Cubitus varus deformity was observed in 1 patient with cross pinning, and loosening of K-wire was seen in 1 patient [Table/Fig-5].

Complications	Number of patients (%)	Cross pinning	Lateral-only pinning
Superficial pin tract infection	4 (13.3%)	3	1
Restriction of movements	3 (10%)	1	2
Iatrogenic ulnar nerve palsy	1 (3.3%)	1	0
Implant loosening	1 (3.3%)	1	0
Cubitus varus	1 (3.3%)	0	1

[Table/Fig-5]: Postoperative complications.

The average time for maximum range of movement recovery was eight weeks for type II fracture and 12 weeks for type III fractures (excluding patients with fixed flexion deformity).

Functional outcome was analysed according to Flynn's criteria. Out of 30 patients included in the study, 25 patients (83.3%) had excellent outcome, 3 (10%) patients had good, 1 (3.3%) had fair and 1 (3.3%) patients had poor functional outcome [Table/Fig-6]. The patients with unsatisfactory results were advised active physiotherapy and reassured. Majority in the cross pin group showed excellent outcome, compared to lateral-only pin.

Results	Number of patients	Cross pinning	Lateral-only pinning
Excellent	25 (83.3%)	19 (90.4%)	6 (66.6%)
Good	3 (10%)	1 (4.7%)	2 (22.2%)
Fair	1 (3.3%)	1 (4.7%)	0
Poor	1 (3.3%)	0	1 (11.1%)

**[Table/Fig-6]:** Functional results based on Flynn's Grading System.

## DISCUSSION

The supracondylar humerus fractures is most commonly seen in children between 5 and 10 years of age. In the present study, the mean age was 7.4 years, which is similar to other studies [12,13]. Supracondylar humerus fracture has higher incidence in males [12,14]. In the present study also had higher incidence in male patients, 21 (70%) male and 9 (30%) female. Most common mode of injury is by fall on outstretched hand in supracondylar fractures [15]. In the present study, 27 (90%) had fall while playing, which is similar to other studies [16,17].

The non-dominant extremity is most commonly affected. In the present study, 22 (73.3%) had left-sided injury and 8 (26.7%) of them had right-sided injury. The findings are reflected in other studies too that show a preponderance of left-sided fractures [12,14,16].

These fractures are mostly caused by low energy trauma and are categorised on the basis of injury pattern, which are extension and flexion types, respectively. Injury caused by extension occurs due to fall on the palm of hand with hyperextended elbow (most common), while direct fall onto fixed elbow results in flexion type of these injuries [18]. In the present study, based on the Gartland's classification, majority had type III fracture (70%) and were of extension type (93.3%).

Controversy persists regarding the optimal pin fixation technique. Commonly used techniques are lateral only pin and cross pinning with one medial and lateral k-wire [19]. Cross pinning configuration with medial pin involved iatrogenic ulnar nerve injury with incidence rate of 0-6% [20]. Lateral pinning technique was observed to have loss of reduction and cubitus varus in 3-5% of patients [20]. Some authors found crossed (medial/lateral) pinning to be superior than two parallel lateral pin fixations [21,22]. However, Reynolds RA and Jackson H, have observed in their study that both type of pin configurations have good outcome in the management of displaced supracondylar humerus fractures in children [23].

In the present study, out of the 30 cases, 21 of them were treated with cross K-wire pinning, 9 of them with lateral only pinning. Out of the 21 patients, who had type III fracture, 4 of them underwent lateral K-wire pinning and 17 underwent crossed K-wire crossed pinning configuration. Supracondylar humerus fractures in children treated commonly with crossed K-wire fixation and is the preferred configuration. Weinberg AM et al., observed in their study that biomechanically crossed K-wires showed more stiffness and least loss of reduction on cyclic loading. The external fixators fixation good alternatives [24]. Zions LE et al., [25] on comparison between crossed K-wire technique with lateral K-wire fixation, found great stability in cross pinning technique. But the authors did not give any clear advantage to lateral technique alone as there were less number of participants in the study.

According to a study, the functional outcome in cross pinning group was excellent in 66.7% and good outcome in 33.3% of patients, and lateral pinning group had 73.3% excellent results and 26.6% good results with no poor results [26]. There was no significant difference in functional outcome between the two groups. This is comparable to present study in which, out of the total 30 cases, 21 (70%) treated with crossed K-wire crossed pinning cases 19 (66.3%) showed excellent results.

Wang YL in their study found mean time to restore elbow range of motion (ROM) recovery after removal of long arm cast without physical therapy in uncomplicated distal humerus supracondylar

and lateral condylar fractures was 5 weeks [27]. In the present study, the mean time for maximum range of movement recovery was 8 weeks for type II fracture and 12 weeks for type III fractures.

Govindasamy R et al., in a retrospective study on cross pinning versus lateral pinning in supracondylar fracture in children and concluded that there was no difference in stability of fixation and both groups had similar outcome functionally and cosmetically [28]. They noticed iatrogenic ulnar nerve injury in 11% of patients in cross pinning group due to medial pin and hence concluded that lateral pinning technique is safer than cross pinning technique. In present study also, 1 case of iatrogenic ulnar nerve injury was noted in cross pinning technique which recovered after K-wire removal.

Pin tract infection occurred in 4 patients (13.3%) in the present study which is comparable with study by Mostafavi HR and Spero C, having 5% incidence of infection around pins [29]. Shannon FJ studied 20 children and found an infection rate of 5%, and granulation tissues were reported in five children out of 20 with no varus deformity [30]. El-Adl WA et al., showed an infection rate and varus deformity of the elbow joint in 8.6% of their patients [31]. In 2011, Dua A et al., showed that in their series of 40 children superficial pin-tract infection rate was 7.5%, with no varus deformity, and a total success rate within 90% [32].

In the present study of 30 cases, the clinical outcome grading was measured as per the Flynn JC et al., criteria for grading outcomes; 25 (83.3%) of the patients observed excellent results. Almohrij SA compared casting and percutaneous pinning in treatment of displaced supracondylar fracture of humerus and concluded percutaneous pinning is a preferable method because it shortens hospitalization time, the elbow can be splinted in a safe and comfortable position, and decrease the risk of compartment syndrome [33].

Skaggs DL et al., studied consequences of pin placement in operative treatment of supracondylar fracture of humerus in children and concluded that lateral pinning is safe and effective for displaced supracondylar fractures; moreover it prevents iatrogenic injury to the ulnar nerve. They also mention that if medial pin is to be used in cross pinning then hyperflexion of elbow is avoided during inserting medial pin [34].

## Limitation(s)

The present study has limitations as it is a retrospective study. There was no statistical comparison between cross pin and lateral-only pin configurations and also at the number of K-wires used in lateral only pinning or sizes of K-wire. There are studies showing more stability with three lateral wires than two lateral wires [35,36], and more stability with thicker (1.6 mm) wires [37,38]. Also, a small sample size prevents to come to a significant conclusion on outcomes.

## CONCLUSION(S)

The present study concludes that displaced supracondylar fracture of humerus in children can be managed safely and effectively with closed reduction and percutaneous K-wire pinning. It was also found that both lateral pinning and cross pinning are safe and effective to get excellent outcomes in supracondylar fracture of humerus in children but lateral pinning is comparatively safe and reliable considering ulnar nerve injury which is more commonly associated with cross pinning. With both techniques, good functional outcome related to early mobilisation of the elbow with a very few complications can be achieved. Displaced supracondylar fractures of the humerus in children treated with closed reduction and percutaneous pin fixation gives excellent functional and cosmetic results.

## REFERENCES

- [1] Waters PM, Mih AD, Beaty JH, Kasser JR. Fractures of the distal radius and ulna. Rockwood Wilkin's Fract Child. 2006;6:337-98.
- [2] Gartland JJ. Management of supracondylar fractures of the humerus. Children Surgery Gynecology & Obstetrics. 1959;109(2):145-54.

- [3] Omid R, Choi PD, Skaggs DL. Supracondylar humeral fractures in children. *J Bone Joint Surg Am.* 2008;90(5):1121-32.
- [4] Schoenecker PL, Delgado E, Rotman M, Sicard GA, Capelli AM. Pulseless arm in association with totally displaced supracondylar fracture. *J Orthop Trauma.* 1996;10(6):410-15.
- [5] Shaw BA, Kasser JR, Emans JB, Rand FF. Management of vascular injuries in displaced supracondylar humerus fractures without arteriography. *J Orthop Trauma.* 1990;4(1):25-29.
- [6] Canale ST. Fractures and dislocations in children. In: Canale ST, Beaty JH, eds. *Campbell's Operative Orthopaedics.* 12<sup>th</sup> ed. Philadelphia (PA): Mosby; 2003:1580-97.
- [7] Flynn JC, Matthews JG, Benoit RL. Blind pinning of displaced supracondylar fractures of the humerus in children: Sixteen years' experience with long-term follow-up. *JBJS.* 1974;56(2):263-72.
- [8] Larson L, Firoozbakhsh K, Passarelli R, Bosch P. Biomechanical analysis of pinning techniques for pediatric supracondylar humerus fractures. *J Pediatr Orthop.* 2006;26(5):e573-78.
- [9] Eberhardt O, Fernandez F, Ilchmann T, Parsch K. Cross pinning of supracondylar fractures from a lateral approach. Stabilisation achieved with safety. *Journal of Children's Orthopaedics.* 2007;1(2):127-33.
- [10] Gordon JE, Patton CM, Luhmann SJ, Bassett GS, Schoenecker PL. Fracture stability after pinning of displaced supracondylar distal humerus fractures in children. *J Pediatr Orthop.* 2001;21(3):313-18.
- [11] Lee SS, Mahar AT, Miesen D, Newton PO. Displaced pediatric supracondylar humerus fractures: Biomechanical analysis of percutaneous pinning techniques. *J Pediatr Orthop.* 2002;22(4):440-43.
- [12] Gopinath P, Singh S, Ravoo A. Study of percutaneous K-wire fixation in supracondylar fracture of humerus in children. *Int J Res Orthop.* 2019;5:427-31.
- [13] Majeed F, Saddique M, Nasir H, Shams A. Comparison of percutaneous cross versus parallel k wire fixation in supracondylar fractures of the humerus in children. *Professional Med J.* 2020;27(3):476-80.
- [14] Babal JC, Mehlman CT, Klein G. Nerve injuries associated with paediatric supracondylar humeral fractures; A meta-analysis. *Journal of Pediatric Orthopedics.* 2010;30:253-63.
- [15] Farnsworth CL, Silva PD, Mubarak SJ. Etiology of supracondylar humerus fractures. *J Paediatr Orthop.* 1998;18:38-42.
- [16] Rao YS, Chakravorthy M. A study of percutaneous K wire fixation in supracondylar fracture of humerus (SCFH) in children. *J Med Allied Sci.* 2015;5(1):06-09.
- [17] Pushkarna VA, Sureja KB. Functional and radiological outcome in displaced supracondylar humerus fracture in children treated with closed reduction and lateral or cross pinning- A retrospective study. *Asian Journal of Orthopaedic Research.* 2020;3(4):19-26.
- [18] Pavone V, Riccioli M, Testa G, Lucenti L, De Cristo C, Condorelli G, et al. Surgical treatment of displaced supracondylar pediatric humerus fractures: Comparison of two pinning techniques. *Journal of Functional Morphology and Kinesiology.* 2016;1(1):39-47.
- [19] Madjar-Simic I, Talic-Tanovic A, Hadziahmetovic Z, Sarac-Hadzihalilovic A. Radiographic assessment in the treatment of supracondylar humerus fractures in children. *Acta Inf Med.* 2012;20(3):154-59.
- [20] Green DW, Widmann RF, Frank JS, Gardner MJ. Low incidence of ulnar nerve injury with crossed pin placement for pediatric supracondylar humerus fractures using a mini-open technique. *J Orthop Trauma.* 2005;19:158-63.
- [21] Chakraborty MK, Onta PR, Sathian B. Displaced supracondylar fracture of humerus in children treated with crossed pin versus lateral pin: A hospital based study from Western Nepal. *J Clin Diagnostic Res West Nepal J Clin Diagn Res.* 2011;5(6):1260-63.
- [22] Balakumar B, Madhuri V. A retrospective analysis of loss of reduction in operated supracondylar humerus fractures. *Indian J Orthop.* 2012;46(6):690-97.
- [23] Reynolds RA, Jackson H. Concept of treatment in Supracondylar humeral fractures. *Injury.* 2005;36(Suppl1):A51-56.
- [24] Weinberg AM, Marzi I, Gunter SM. Supracondylar humerus fracture in childhood and efficacy study. Results of a multicenter study by the Pediatric Traumatology Section of the German Society of Trauma Surgery I: Epidemiology, effectiveness evaluation and classification. *Unfallchirurg.* 2002;105:208-16.
- [25] Zions LE, McKellop HA, Hathaway R. Torsional strength of pin configurations used to fix supracondylar fractures of the humerus in children. *J Bone Joint Surg Am.* 1994;76(2):253-56.
- [26] Pathania VP, Dubey N, Gupta S. Treatment of displaced supracondylar fracture of humerus in children by lateral entry pinning versus cross pinning. *Int J Sci Stud.* 2016;4(1):70-74.
- [27] Wang YL. The recovery of elbow range of motion after treatment of supracondylar and lateral condylar fractures of the distal humerus in children. *J Orthop Trauma.* 2009;23(2):120-25.
- [28] Govindasamy R, Gnanasundaram R, Kasirajan S, Thonikadavath F, Tiwari RK. Cross pinning versus lateral pinning in type III supracondylar fracture: A retrospective analysis. *Int J Res Orthop.* 2016;2(3):138-42.
- [29] Mostafavi HR, Spero C. Crossed pin fixation of displaced supracondylar humerus fractures in children. *Clin Orthop Relat Res.* 2000;376:56-61.
- [30] Shannon FJ. Dorgan's percutaneous lateral cross wiring of supracondylar fractures of the humerus in children. *J Pediatr Orthop.* 2004;24:376-79.
- [31] El-Adl WA, El-Said MA, Boghdady GW, Ali AS. Results of treatment of displaced supracondylar humeral fractures in children by percutaneous lateral cross-wiring technique. *Strategies Trauma Limb Reconstr.* 2008;3:01-07.
- [32] Dua A, Eachempati KK, Malhotra R, Sharma L, Gidaganti M. Closed reduction and percutaneous pinning of displaced supracondylar fractures of the humerus in children with delayed presentation. *Chin J Traumatol.* 2011;14:14-19.
- [33] Almohrij SA. Closed reduction with and without percutaneous pinning in Supracondylar fractures of the humerus in children. *Annals of Saudi Medicine.* 2000;20:70-73.
- [34] Skaggs DL, Julia MH, Jeffrey B, Cornelia K, Robert MK, Vernon TT. Operative treatment of Supracondylar fractures of humerus in children. The consequences of pin placement. *JBJS.* 2001;83A:735-40.
- [35] Gaston RG, Cates TB, Devito D. Medial and lateral pin versus lateral-entry pin fixation for Type 3 supracondylar fractures in children: A prospective, surgeon-randomized study. *J Pediatr Orthop.* 2010;30(8):799-806.
- [36] Lee YH, Lee SK, Kim BS. Three lateral divergent or parallel pin fixations for the treatment of displaced supracondylar humerus fractures in children. *J Pediatr Orthop.* 2008;28(4):417-22.
- [37] Bloom T, Robertson C, Mahar AT, Pring M, Newton P. Comparison of supracondylar humerus fracture pinning when the fracture is not anatomically reduced. *J Pediatr Orthop.* 2008;28(7):766-72.
- [38] Srikumaran U, Tan EW, Erkula G, Leet AI, Ain MC, Sponseller PD. Pin size influences sagittal alignment in percutaneously pinned pediatric supracondylar humerus fractures. *J Pediatr Orthop.* 2010;30(8):792-98.

**PARTICULARS OF CONTRIBUTORS:**

1. Assistant Professor, Department of Orthopaedics, Hassan Institute of Medical Sciences, Hassan, Karnataka, India.
2. Associate Professor, Department of Orthopaedics, Hassan Institute of Medical Sciences, Hassan, Karnataka, India.
3. Associate Professor, Department of Orthopaedics, Hassan Institute of Medical Sciences, Hassan, Karnataka, India.

**NAME, ADDRESS, E-MAIL ID OF THE CORRESPONDING AUTHOR:**

K Shankara,  
71, HIMS Doctors Quarters, Sri Chamarajendra Hospital Campus,  
Hassan, Karnataka, India.  
E-mail: drkshankara1959@gmail.com

**AUTHOR DECLARATION:**

- Financial or Other Competing Interests: None
- Was Ethics Committee Approval obtained for this study? Yes
- Was informed consent obtained from the subjects involved in the study? Yes
- For any images presented appropriate consent has been obtained from the subjects. Yes

**PLAGIARISM CHECKING METHODS:** [Jain H et al.]

- Plagiarism X-checker: Nov 11, 2020
- Manual Googling: Feb 12, 2021
- iThenticate Software: Mar 19, 2021 (24%)

**ETYMOLOGY:** Author Origin

Date of Submission: **Nov 18, 2020**  
Date of Peer Review: **Dec 31, 2020**  
Date of Acceptance: **Mar 05, 2021**  
Date of Publishing: **May 01, 2021**